

## Sjögren's syndrome: Infections that may play a role in pathogenesis, mimic the disease, or complicate the patient's course

Robert I Fox, Carla M Fox

### ABSTRACT

Sjögren's syndrome (SS) is a systemic autoimmune disorder characterized by lymphocytic infiltration of the lacrimal and salivary glands, leading to dryness of the eyes and mouth. Epidemiologic studies have indicated a role of both genetic and environmental factors in pathogenesis. It is likely that viral infection can create an inflammatory micro-environment that alters the disposition of apoptotic fragments that serve as autoantigens. Thus, the search for a single viral agent that is causative is likely to prove difficult. Attention has focused on viruses that have tropism for the salivary and lacrimal glands, particularly members of the herpesvirus family. Other infectious agents too may mimic the clinical appearance of SS or complicate the disease. This article reviews the role of infections in patients with Sjogren's syndrome.

**Keywords:** Sjogren's syndrome, infections

### INTRODUCTION

Sjögren's syndrome (SS) is a systemic autoimmune disorder characterized by lymphocytic infiltration of the lacrimal and salivary glands, leading to dryness of the eyes and mouth.

SS patients have a characteristic pattern of lymphocytic infiltrates in the glands, characteristic autoantibodies, and extraglandular manifestations. These patients also have an increased frequency of lymphoproliferative disorders ranging from enlarged glands to non-Hodgkin's lymphoma.

Epidemiologic studies have indicated a role of both genetic and environmental factors in pathogenesis.

Viral agents that have been proposed as co-factors include:

1. Epstein-Barr virus
2. Retroviruses (including HTLV-1, HTLV-5 and endogenous retroviruses)
3. Coxsackie virus

Viruses that may mimic SS include hepatitis C and human immunodeficiency virus (HIV) as part of the AIDS-related complex (ARC).

In addition, the finding of a positive anti-nuclear antibody (ANA) or rheumatoid factor (RF) with other infectious

conditions may lead to confusion in the true underlying diagnosis including:

1. Tuberculosis (TBC),
2. Leprosy (*Mycobacterium leprae*),
3. Syphilis or other spirochetes such as Lyme,
4. Hepatitis A, B or C
5. Parvovirus B19
6. Dengue fever
7. Sub-acute bacterial endocarditis
8. Drugs used to treat infection such as minocycline and isoniazid

Sjogren's syndrome serves as a cross road between immune, endocrine and neural processes. One or more environmental factors play a role in triggering the inflammatory cascade that results in a chronic autoimmune disease where the innate and acquired immune system enter a vicious non-ending cycle. Since the immune system has a limited number of responses with associated clinical manifestations, it is not surprising that certain infectious agents can trigger the interferon mediated pathways (especially type I and gamma interferon) that resemble SS. Further, SS patients may develop infectious diseases that mimic glandular and extraglandular features of SS and require specific therapy.

**BACKGROUND**

Sjögren’s syndrome (“SS”) is an autoimmune disorder that develops when one’s genetic predisposition combines with environmental or infectious factors. Further, there are neural and hormonal connections that influence the onset and severity of the disease.

Physicians and patients have long recognized that simply having the susceptibility genes was not enough to guarantee the emergence of clinical disease. The simplest example is the lack of “concurrence” of SS (or SLE) in identical twins.<sup>1</sup>

1. Each identical twin shares the same genome, but has different exposure to environmental agents and slightly

**Table 1** Infectious agents implicated as environmental co-factors in Sjögren’s syndrome

1. Epstein-Barr virus
2. Human T-leukaemia virus (HTLV-1)
3. Coxsackie virus
4. Endogenous retrovirus

**Table 2** Infectious agents that may mimic Sjögren’s syndrome

1. Tuberculosis (TBC) <sup>78,80,81</sup>
2. Leprosy ( <i>M. leprae</i> ) <sup>13,83,85</sup>
3. Syphilis or other spirochetes such as Lyme <sup>93</sup>
4. Hepatitis A, B or C <sup>61,94,95</sup>
5. Parvovirus B19 <sup>96</sup>
6. Dengue fever <sup>97</sup>
7. Malaria <sup>12</sup>
8. Sub-acute bacterial endocarditis <sup>15</sup>
9. Drugs used to treat infection such a minocycline and isoniazid <sup>98</sup>

different ways in which their genes are activated (or rearranged) as they respond to infections and hormonal changes.

2. If only genetic factors were required, then we would expect that if one twin develops SS, then the other twin would always develop SS as well.
3. Although the second identical twin does have an increased risk for development of SS (which is called the “concordance rate”), the observed frequency of SS (or SLE) in the other twin is only about 15–25%.<sup>2</sup>

So roughly speaking,

1. 20% of the disease can be considered strictly genetic i.e., encoded by a person’s genome;
2. 80% is due to some other factors such environmental influence—including exposure to infections or hormonal changes.

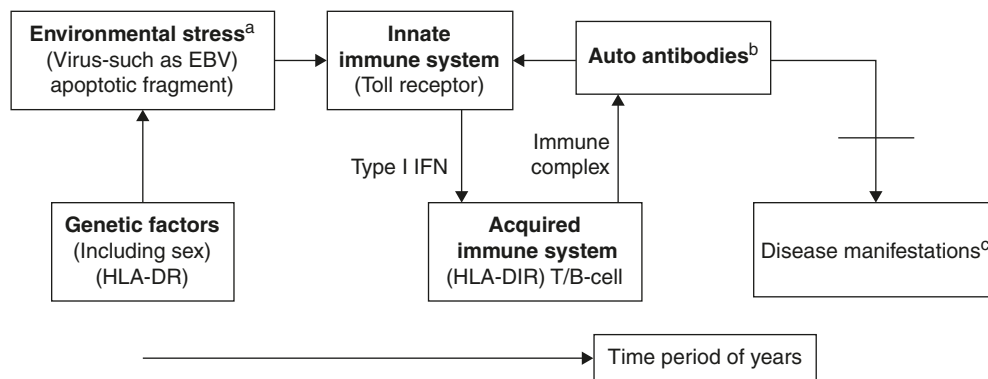
A schematic that shows the “time line” is shown in Figure 1.

The patient starts with the genetic tendency (i.e., female, and perhaps HLA-DR3 in Caucasian populations). These factors predispose the patient to make a particular set of auto-antibodies... such as the anti-nuclear antibody (ANA) and the antibody to Sjögren’s syndrome-associated antigen A (SS-A), which we now recognize as actually two different proteins with molecular weight 60,000 and 52,000 Da, respectively.

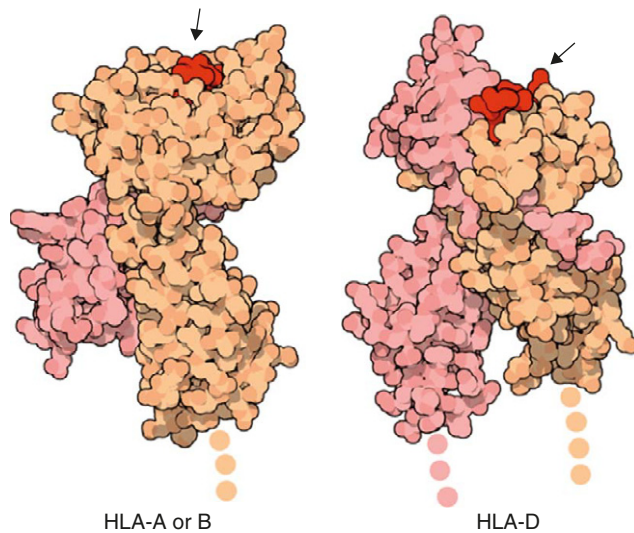
In some SS patients, a second Sjögren’s associated antigen termed SS-B, with molecular weight 45,000 Da, is also found.

Both of these antigens bind to a double-stranded RNA termed HyRNA to form a protein RNA complex that may be mistaken by the immune system as a viral ribonuclear protein.<sup>3</sup>

The formation of these autoantibodies implies a set of T-cells that have receptors that exhibit cross-reactivity with the self-antigens by escaping the normal mechanisms of central and peripheral “tolerance.”



**Figure 1** Time course of autoimmune response. <sup>a</sup>Environmental stress is interpreted in context of genetic factors; <sup>b</sup>Antibodies precede disease; <sup>c</sup>Presence of antibodies does not mean disease.



**Figure 2** The histocompatibility antigens bind small peptides.

It is notable that most of the autoantigens are derived from apoptotic debris of cells, reflecting the role of the immune cell in the normal homeostatic clearance of these nucleoproteins in a manner that does not lead to autoimmunity.<sup>4-7</sup>

Thus, viral or other infections may lead to destabilization of the immune regulatory process either as a direct result of “molecular mimicry” (where the structure of the viral product binds to a T-cell receptor) or “innocent bystander” (where the infection engenders a microenvironment release of cytokines that “breaks” tolerance to the apoptotic product).<sup>8</sup> The reason for association of specific HLA-DR associations with this vicious cycle is that only certain peptides bind with the binding site of HLA-DR beta chains with intermediate avidity and allow presentation to T-cells that may then be triggered to provide help to B-cells. Indeed, the association of particular autoantibodies is more closely associated with the HLA-DR of the host than the clinical manifestations.<sup>9-11</sup>

## INFECTIONS THAT MAY IMITATE/MIMIC SJÖGREN'S SYNDROME

Epidemiologic studies have indicated a role of both genetic and environmental factors in pathogenesis. Viral agents that have been proposed as co-factors include Epstein-Barr virus, retroviruses (including HTLV-1 and endogenous retroviruses), and Coxsackie virus. Viruses that may mimic SS include hepatitis C and human immunodeficiency virus (HIV) as part of the AIDS related complex (ARC).

In addition, the finding of a positive anti-nuclear antibody (ANA) or rheumatoid factor (RF) with other infectious conditions including tuberculosis (TBC),<sup>12</sup> leprosy (*Mycobacterium leprae*),<sup>13</sup> malaria,<sup>12</sup> syphilis, hepatitis A or B<sup>14</sup> or sub-acute bacterial endocarditis<sup>15</sup> may lead to confusion in the true underlying diagnosis of a patient labelled with SS.

Paraneoplastic syndromes, myeloma or lymphomas with anti-nuclear antibodies may also be confused with SS.

In SS patients, distinction between disease progression and super-infection may further complicate diagnosis. This is particularly true when the patient is receiving corticosteroids or other immune suppressive/modulatory medications.

1. Ocular symptoms related to herpetic infections may lead to serious consequences.
2. Oral candidiasis commonly exacerbates dry or painful mouth.
3. Tuberculosis reactivation (either pulmonary or extra-pulmonary) may occur in patients on corticosteroids or tumour necrosis factor inhibitors.
4. Reactivation of papilloma viruses (such as BK or JK virus) may occur in patients on B-cell depleting therapies leading to catastrophic central nervous system changes.

Particular care in vaccination is required in immune suppressed patients. Live viruses are to be avoided when possible. Required vaccines such as pneumococcal should be given prior to biologic agents when possible (Section 4).

### A. Herpes viruses: Epstein-Barr virus

Epstein-Barr virus (EBV), also called human herpes virus 4 (HHV-4), is a member of the herpes family, which includes herpes simplex virus 1 and 2, and is one of the most common viruses in humans. Epstein-Barr virus occurs worldwide and causes infectious mononucleosis (glandular fever). It is also known to cause several lymphoproliferative disorders and cancers, particularly Hodgkin's disease, Burkitt's lymphoma, nasopharyngeal carcinoma and central nervous system lymphomas associated with HIV.

Most people become infected with EBV and gain adaptive immunity before 10 years of age. In the United States, as many as 95% of adults between 35 and 40 years of age have been infected. Infants become susceptible to EBV as soon as maternal antibody protection disappears.<sup>16</sup> Many children become infected with EBV, and these infections usually cause no symptoms or are indistinguishable from the other mild, brief illnesses of childhood.

In the United States and in other developed countries, many persons are not infected with EBV in their childhood

years. However, when infection with EBV occurs during adolescence or young adulthood, it causes infectious mononucleosis 35% to 69% of the time. Thus, the age of exposure to EBV may lead to an autoimmune disorder (i.e., the autoantibody detected as “heterophile”) and lymphoproliferation.

In Sjögren’s syndrome,<sup>17</sup> the interest in EBV reflects the ability of the salivary glands to harbour this infection—indeed the transmission from EBV carriers to uninfected individuals, has led infectious mononucleosis to be known as the “kissing disease,” as it occurs when previously uninfected adolescents receive viral infection via saliva in the act of kissing.

Also, EBV infection of lymphocytes from normal or SS patients can generate a wide range of autoantibodies including anti-nuclear antibodies (ANA)<sup>18</sup> and high levels of immunostimulatory cytokines.<sup>19</sup>

Salivary gland biopsies from SS patients have a higher number of copies of EBV DNA, although still only about one copy of EBV DNA per million cells based on quantitative polymerase chain reaction<sup>20,21</sup> or *in situ* hybridization.<sup>22</sup> Similar findings have been reported in SS lacrimal gland biopsies.<sup>23,24</sup> However, another study did not confirm increased number of EBV genomes or the presence of early EBV encoded RNA’s (called EBERs) in salivary gland biopsies.<sup>25,26</sup>

SS patients have an increased number of circulating B-cells that harbour EBV<sup>27,28</sup> and a slightly different pattern of autoantibodies against EBV encoded early antigens.<sup>29–33</sup> There have been cases in which primary EBV infection has been followed by SS.<sup>34,35</sup> The overall problem is that EBV has latency and periodic reactivation in both normal individual’s and SS patient’s salivary and lacrimal glands. Therefore, it is difficult to determine whether the increased number of EBV infected cells (which seems to be a consensus among most studies) is a cause or effect of the immune dysregulation.<sup>36</sup>

## B. Retroviruses

Two retroviruses, human immunodeficiency virus (HIV) and human T-cell leukaemia virus (HTLV-1), are known to be causes of a syndrome that presents with a clinical picture similar to that seen in Sjögren’s syndrome. Since the pathogenesis of HIV associated “Aids Related Complex” (ARC) is now considered to be distinct from SS, this virus will be discussed below.

HTLV was discovered in 1977 in Japan. The virus was first isolated by Drs. Bernard Poiesz and Francis Ruscetti and their co-workers in the laboratory of Robert C. Gallo at the National Cancer Institute. It was the first identified human retrovirus.

Infection with HTLV-I, like infection with other retroviruses, probably occurs for life, and can be inferred when antibody against HTLV-1 is detected in the serum.

The human T-lymphotropic virus (HTLV-I) is a retrovirus that infects 10–20 million people worldwide from seroprevalence studies. Despite this prevalence, especially in some endemic areas, HTLV-I is associated with disease in only approximately 5% of infected individuals.

The majority of HTLV-I-infected individuals will remain asymptomatic, but there are two well-recognized disease associations caused by the virus:

- Adult T-cell leukaemia/lymphoma (ATLL)
- HTLV-I-associated myelopathy (HAM), also known as tropical spastic paraparesis (TSP).

Evidence for an association with HTLV-1 and SS is strongest in the southern islands of Japan where HTLV-1 is endemic.<sup>37,38</sup> Saliva in SS patients infected with HTLV-1 contains increased levels of specific antibody.<sup>39</sup> However, SS occurs in the southern islands of Japan in HTLV-1 negative patients as well, and it is only a slightly higher frequency of SS associated with the virus.

About 10 years ago, Garry et al.<sup>40</sup> reported a human intracisternal A-type retroviral particle (termed retrovirus type 5) that was antigenically related to HIV, and was detected by co-culture of homogenates of salivary tissue from patients with Sjögren’s syndrome and an unrelated cell line. Comparison of this retroviral particle to HIV indicates that they were distinguishable by several ultra structural, physical, and enzymatic criteria.<sup>41</sup> However, subsequent studies have not confirmed the reports from a single centre,<sup>42</sup> and it has been concluded that the detected virus was re-activated from the cell line used for co-culture.

The normal human genome is scattered with fragments of DNA with homology to retroviruses but the vast majority of these fragments have “lethal” mutations that prevent coding of functional viral proteins.<sup>43,44</sup> However, at least one DNA fragment (called a retroposon HERV-K)<sup>45,46</sup> appears capable of encoding a retroviral proteins<sup>47</sup> and antibodies to a retroviral “gag” protein have been reported in some Japanese SS patients.<sup>48</sup> The significance of these retroviral proteins in pathogenesis remains unclear. It is hard to rule out an indirect role in pathogenesis since the endogenous retrovirus may become activated in particular conditions, as indicated by the detection of a retroviral 3 encoded protein in a SS patient with fetal loss associated with neonatal heart block)<sup>49</sup> or their ability to influence the transcription of adjacent genes such as MHC gene complex.<sup>50</sup>

The creation of a transgenic mouse expressing the HTLV-1 tax gene and with lymphoproliferative features including a SS-like syndrome, generated significant interest in endogenous retroviruses and autoimmunity.<sup>43</sup> However, expression of this tax gene was not found in SS patients.<sup>51</sup> A separate serologic study reported an increased frequency of antibody against HTLV-1 encoded p19 protein,<sup>52</sup> but the significance

of this cross reaction remains unknown and has not been replicated.

### C. Coxsackie virus

Coxsackie virus is a virus that belongs to a family of non-enveloped linear single-stranded positive-sense ssRNA, Picornaviridae, and the genus enteroviruses, which also includes poliovirus, echovirus and hepatitis A virus are among the most common and important human pathogens and ordinarily the fecal-oral route transmits its members.

Coxsackie virus infections most commonly occur in children as oval shaped pale papules with a rim of erythema on the palms and soles, and small aphthae intraorally, otherwise known as hand, foot and mouth disease. Fever is common along with sore throat and a malaise that often precedes the onset of lesions. Lesions tend to spare the lips and gingiva, in contrast to HSV.<sup>8</sup>

A recent study<sup>53</sup> of Greek SS patients reported 94-bp fragment of Coxsackie virus B4 (CVB4). P2A gene was cloned from minor salivary gland biopsies in the 7/7 primary SS samples. This gene fragment was not detected in samples from patients with secondary SS or controls.

Immunohistochemistry for the enteroviral capsid protein VP1 revealed positive staining in epithelial cells and lymphocytic infiltrates in 11 primary SS samples, 1 secondary SS sample, and no control samples. However, other gene sequences encoded by coxsackie were not detected by cloning methods.

In a separate study, a cross-reactivity between a coxsackie structural protein and the SS-A antigen was demonstrated among Greek patients.<sup>54</sup> However using similar methods of gene cloning and antibody detection, these findings were not replicated in a non-Greek population.<sup>55</sup> At present, it is not possible to determine whether the reported differences are due to distinct ethnic patient populations or methodologic differences.

### D. Hepatitis C

The hepatitis C virus is a small (50 nm in size), enveloped, single-stranded, positive sense RNA virus. It is the only known member of the hepacivirus C virus genus in the family Flaviviridae.

There are six major genotypes of the hepatitis C virus, which are indicated numerically (e.g., genotype 1, genotype 2, etc.). The hepatitis C virus is transmitted by blood-to-blood contact.

1. In undeveloped countries, it is estimated that 90% of persons with chronic HCV infection were infected through

transfusion of unscreened blood or blood products or via injecting drug use or sexual exposure.

2. In developing countries, the primary sources of HCV infection are unsterilised injection equipment and infusion of inadequately screened blood and blood products.

There has not been a documented transfusion-related case of hepatitis C in the United States for over a decade as the blood supply is vigorously screened with both EIA and PCR technologies.

- Although injected drug use is the most common routes of HCV infection in the US, any practice, activity, or situation that involves "blood-to-blood exposure" can potentially be a source of HCV infection.

The clinical association of SS and hepatitis C virus reflects the increased frequency of dry eyes and dry mouth in hepatitis C patients, as well as detection in a subset of infected patients autoantibodies to ANA or RF. However, these patients lack antibody to SS-A and SS-B. Their salivary gland biopsies show focal lymphocytic infiltrates similar to non-hepatitis infected SS patients.<sup>56-58</sup>

The saliva and salivary gland biopsy of infected patients may contain hepatitis C genomes,<sup>59</sup> but this occurs in a minority of patients with sicca symptoms. There is possible molecular mimicry between a hepatitis C structural protein and salivary gland antigens.<sup>60,61</sup>

Hepatitis C has been listed as an exclusion from the criteria for diagnosis of primary SS in the current American-European Consensus criteria, in order to focus attention of clinicians on liver and particular therapeutic needs of the hepatitis C patients.<sup>62</sup>

1. However it is important to recognize that in the earlier criteria for SS used by the European consortium in the 1980's, hepatitis C was not excluded, and thus, the frequency of liver involvement and clinical outcome was significantly different than in current criteria where hepatitis C is excluded.<sup>61</sup>

2. For example, up to 25% of SS patients in several European studies (particularly studies from Italy) had hepatitis C infection and this dramatically skewed clinical outcomes.<sup>63</sup>

Of clinical importance, patients with hepatitis C may have rashes of mixed cryoglobulinemia (particularly type II with a monoclonal rheumatoid factor)<sup>64</sup> or thrombocytopenia due to immune destruction<sup>65</sup> that may lead to their presentation to the rheumatologist as SS patients based on their positive ANA and symptoms of dryness.

On the other hand, in the patient with recognized hepatitis C, all of these clinical problems may be exacerbated by treatment with interferon gamma (an immune stimulant).<sup>66,67</sup> Thus, hepatitis C serves as a crossroad between infectious disease and autoimmune response.<sup>68,69</sup>

### E. Herpes Virus: Cytomegalovirus and Human Herpes Virus-6

Cytomegalovirus (HCMV) and human herpes virus 6 (HHV-6) are additional members of the Herpesvirus family. CMV belongs to the Beta-herpesvirinae subfamily of Herpesviridae, which also includes Roseolovirus.

Other herpes viruses fall into the subfamilies of Alpha-herpesvirinae (including HSV-1 and -2 and Varicella) or Gamma-herpesvirinae (including Epstein-Barr virus).

All herpes viruses share a characteristic ability to remain latent within the body over long periods. HCMV infections are frequently associated with salivary glands where they may present as “atypical mononucleosis”.<sup>70</sup>

A possible association with SS was associated based on the salivary gland site of infection and latency of CMV, as well as mildly increased antibody titers in SS patients.<sup>71</sup> Although early studies on antibody titers and onset of SS suggested a causal association,<sup>72</sup> subsequent studies have found it difficult to distinguish the titer and pattern of anti-CMV antibodies in age matched normal and SS patients after the correction for hyperglobulinemia associated with SS.<sup>73</sup>

Human herpes virus six (HHV-6) is one of the eight known viruses that are members of the human herpes virus family. It causes the disease exanthem subitum (“Roseola”), a near-universal childhood disease.

Although up to 100% of the population are exposed (seropositive) to HHV-6, most by 3 years of age, there are rare cases of primary infections in adults.

In the United States, these have been linked more with HHV-6A, which is thought to be more pathogenic and more neurotropic, and has been linked to several central nervous system related disorders.

HHV-6 has been reported in multiple sclerosis patients and has been suggested as a co-factor in several other diseases, including chronic fatigue syndrome, and but no definitive link has been established.

The association of SS and HHV-6 was initially proposed due to the initial cloning of this virus from a lymphoma occurring in an SS patient.<sup>74</sup> The tropism of HHV-6 for CD4 T-cells made this candidate attractive.<sup>8</sup>

However, subsequent studies on other SS patients and lymphoma did not show either increased genomes or serologic changes from age matched controls.<sup>74</sup> Thus, the difficulties in causally associating CMV or HHV-6 and SS are similar to those found with EBV associations. Members of the Herpesvirus are endemic in both normal and patient populations.

Changes in serology of herpes viruses and flares of SS are subtle and may be the result of the activation of the

autoimmune process rather than reflective of the cause of the flare of SS.

### F. Retrovirus: HIV and AIDS related complex

Human immunodeficiency virus (HIV) is a lentivirus (a member of the retrovirus family) that causes AIDS infection with HIV and occurs by the transfer of blood, semen, breast milk or other bodily fluids. Screening of blood products for HIV has largely eliminated transmission through blood transfusions or infected blood products in the Western world, but the risk remains in many portions of the “Third World.”

AIDS-related complex,<sup>75</sup> or ARC, was recognised when the medical community became aware that a subset of HIV-infected patients exhibited hyperactive T-cell and B-cell humoral immune responses, compared to depressed or normal antibody reactivity in AIDS.

Autoantibodies to ANA or ANCA may be present in up to 25% of these ARC patients,<sup>76</sup> although they infrequently express antibodies to SS-A or SS-B antigens. ARC patients may have markedly enlarged salivary glands as well as lymphadenopathy.

Also, the immune pathology of salivary gland biopsies shows a predominance of CD8+ T-cells, in contrast to SS biopsies where CD4+ T-cells predominate.<sup>75</sup> Consequently, the presence of HIV infection is considered exclusion to the diagnosis of SS. Although the clinical suspicion for ARC may be high in homosexual males, this diagnosis needs to be considered in females who do not provide a history of risk factors, in order to optimize patient treatment and protect the medical staff from exposure to blood products.

### F. Mycobacteria (*M. tuberculosis* and *M. leprae*)

*Mycobacterium tuberculosis* and atypical mycobacterium are well-known causes of cervical lymphadenopathy, most often presenting without symptoms of systemic infection.<sup>77</sup> TBC may also directly involve the parotid or submandibular glands.<sup>78</sup> These organisms may also directly involve the parenchyma of the major salivary glands and their periglandular or intraglandular nodes.

The diagnosis of mycobacterial infections of the major salivary glands, compared to cervical lymph nodes, is equally—if not more—difficult to make. The differential must include the same spectrum of inflammatory and neoplastic diseases as well as lesions unique to the salivary glands.

In particular, cutaneous fistulas may result from incisional biopsy or incision and drainage of the involved gland. Partial parotidectomy or submaxillary gland excision may

be required, followed by multi-drug, anti-tuberculous chemotherapy for 1 to 2 years.

Culturing of the organisms is extremely difficult, and the diagnosis of either mycobacterium tuberculosis or atypical mycobacterial infection must be based on a combination of history and clinical examination, skin testing, histopathology, acid-fast stains, culture, and response to surgery and anti-tuberculous chemotherapy. Polymerase chain reaction (PCR) may prove the most rapid method of diagnosis.<sup>79</sup> The patient may be initially diagnosed as having SLE or SS due to the high frequency of autoantibodies (up to 50% with ANA or rheumatoid factor).<sup>80–82</sup> Indeed, retrospective analysis of the original case of Mickulicz syndrome occurring in a German male farmer that may have actually been a case of extraglandular TBC.<sup>8</sup>

### G. Spirochetes (Syphilis)

The signs and symptoms of syphilis (*Treponema pallidum*) are numerous; before the advent of serological testing, precise diagnosis was very difficult. In fact, the disease was dubbed the “Great Imitator” because it was often confused with other diseases, particularly in its tertiary stage. Systemic symptoms include fever, headache, malaise, anorexia, sore throat, myalgias, and weight loss. These clinical manifestations probably reflect the brisk immunologic response resulting from widespread dissemination of *T. pallidum*. Further confusion can develop because a false positive RPR is a relatively common finding in SS or SLE patients indicating a common type of immune response in both infection and autoimmune conditions.

The clinical symptoms of syphilis can include rash and adenopathy, as well as ocular manifestations and musculoskeletal symptoms. Invasion of the cerebrospinal fluid (CSF) is common in early stages of the untreated disease.

In contrast to the keratoconjunctivitis sicca of SS, the ocular symptoms usually include anterior uveitis, posterior uveitis, or panuveitis, which is often granulomatous. The most common ocular manifestations include posterior uveitis (multifocal chorioretinitis), but other manifestations include retinal necrosis and optic neuritis.

Oral manifestations of syphilis may occur, including split, fissured papules of the oral commissures or oral erosions. However, these are generally accompanied by peripheral rash in secondary syphilis that can take virtually any form, except vesicular lesions. The peripheral rash is classically a diffuse, symmetric macular or papular eruption involving the entire trunk and extremities, including the palms and soles although localized lesions can also occur.

Individual lesions are discrete red or reddish-brown and measure 0.5–2 cm in diameter. They are often scaly but may be smooth and rarely pustular (e.g., “pustular syphilids.” Pustular syphilis can take the form of small pustular syphilide, large pustular syphilide, flat pustular syphiloderma, and pustular-ulcerative syphilide (i.e., malignant syphilis). Nodular lesions also may be seen. The involvement of the palms and soles is an important clue to the diagnosis of secondary syphilis.

The distinction of SS or SLE from syphilis may be difficult, particularly when evaluating vague symptoms including CNS or peripheral nerve involvement. The finding of a positive RPR may also occur in SS or SLE. Thus, the detection of FTA is indicated since the RPR may prove negative if the patient has previously received partial treatment.

### H. Leprosy (*Mycobacterium leprae*)

The acid-fast bacillus, *M. leprae*, causes leprosy or Hansen's disease. Tuberculoid leprosy is often linked to HLA-DR3; lepromatous leprosy is associated with HLA-DQ1. HLA-DR3 has been associated with SS in Caucasians and formation of autoantibodies to ANA.

Leprosy may present with both oral<sup>83</sup> and ocular lesions.<sup>83–85</sup>

Ocular lesions could include keratitis (especially interstitial keratitis and scleritis) in addition to uveitis and retinitis. Oral leprosy may present as an oral candidiasis.<sup>86</sup> The diagnosis of leprosy needs to be considered in any patient who has lived in endemic regions. Leprosy should always be considered in any patient with skin lesions including loss of eyebrows and/or enlarged nerve(s) accompanied by sensory loss. The disease can also involve other areas, such as the eyes, nose, and testicles. Although relatively uncommon, advanced MB cases may demonstrate nasal-septal perforation with collapsed nose (saddle nose deformity), and hoarseness (laryngeal involvement).

### I. Trachoma

Although the pathogenesis of trachoma is distinct from SS, it is worth remembering that trachoma remains one of the world's leading cause of ocular symptoms and blindness.

Trachoma infections result in entropion—a painful form of ocular pathology when the eyelids turn inward, causing the eyelashes to scratch the cornea. Although the changes are easily distinguished by the ophthalmologist, the rheumatologist in the West may not consider this diagnosis in the patient who presents with “dry painful eyes.”

Trachoma is caused by *Chlamydia trachomatis*, and it is spread by direct contact with eye, nose, and throat secretions from affected individuals, or contact with fomites (inanimate objects), such as towels and/or washcloths, that have had similar contact with these secretions.

Although trachoma was eliminated from much of the developed world in the last century, this disease persists in many parts of the developing world particularly in communities without adequate access to water and sanitation. In many of these communities, women are three times more likely than men to be blinded by the disease, due to their roles as caretakers in the family.

## INFECTIONS THAT COMPLICATE SJÖGREN'S SYNDROME

### A. Candida

About one-third of patients with chronic hyposalivation develop oral candidiasis, usually of the chronic erythematous type (and usually not of the pseudo membranous type—white thrush).

1. Symptoms of chronic erythematous oral candidiasis include:
  - a. a burning sensation of the mucosa,
  - b. intolerance to acidic or spicy foods, and
  - c. a change in taste or development of a metallic taste.
  - d. some cases are asymptomatic.
2. Clinical signs of candidiasis of the erythematous type include:
  - a. macular erythema on the dorsal tongue, palate, buccal mucosa, or denture-bearing mucosa,
  - b. atrophy of the filiform papillae on the dorsal tongue, and/or
  - c. angular cheilitis.
3. The diagnosis can be confirmed by fungal culture of a swab specimen, from such a mucosal lesion, revealing significant numbers of colony-forming units of a candida species, usually *Candida albicans*.

**Table 3** Infectious agents that may complicate Sjögren's syndrome

1. Candida (oral)
2. Herpes zoster or simplex of the eye (or skin)
3. Tuberculosis reactivation
4. Atypical mycobacteria
5. Coccidiomycosis reactivation
6. Septicemia, whose normal manifestations may be blunted by their therapy

### B. Herpes Simplex Virus

Herpes simplex is a viral disease caused by both herpes simplex virus type 1 (HSV-1) and type 2 (HSV-2). Infection with the herpes virus is categorized into one of several distinct disorders based on the site of infection.

Primary ocular HSV infections occur in less than 5% of patients, but can cause significant morbidity due to keratitis and acute retinal necrosis.

Keratitis—Recurrent HSV-1 keratitis continues to be a leading cause of corneal blindness in industrialized nations. HSV keratitis has an acute onset with symptoms of pain, visual blurring, and discharge. Physical examination is notable for chemosis, conjunctivitis, decreased corneal sensation, and characteristic dendritic lesions of the cornea.

Oral Herpes, the visible symptoms of which are colloquially called “cold sores” or “fever blisters,” infects the face and mouth. Oral herpes is the most common form of infection.

Herpetic gingivostomatitis is often the initial presentation during the first herpes infection. It is of greater severity than herpes labialis, which is often the subsequent presentation.

Primary infection typically presents as swelling of the conjunctiva and eyelids (blepharconjunctivitis), accompanied by small white itchy lesions on the surface of the cornea.

Bell's Palsy, a type of facial paralysis, may be related to reactivation of herpes simplex virus type 1. This theory has been contested, however since HSV is detected in large numbers of individuals who never experienced facial paralysis, and higher levels of antibodies for HSV are not found in HSV-infected individuals with Bell's palsy compared to those without.

### C. Varicella Zoster

Varicella zoster virus (VZV) is one of eight herpes viruses known to infect humans (and other vertebrates). It commonly causes chicken in children and both shingles and post-herpetic neuralgia in adults and rarely in children.

## PARANEOPLASTIC SYNDROMES

Paraneoplastic syndromes, myeloma or lymphomas with anti-nuclear antibodies may also be confused with SS. Although this chapter deals with infectious diseases, there is ample evidence that viral infections may play a role in certain underlying malignancies. The clinical dilemma arises when a patient is being evaluated for unusual symptoms such as neuropathy (central or peripheral) or an infiltrating disease of an



extraglandular site and a positive autoantibody such as an ANA or RF is detected. The patient may erroneously diagnosed as SS and the possibility of underlying infection or paraneoplastic syndrome is not further pursued:

1. Antineuronal antibodies associated with carcinomas of lung, ovary and prostate such as anti-Hu D antigen that cross react with SS-A.<sup>87</sup>
2. Monoclonal gammopathies associated with Waldenstrom's macroglobulinemia or myelodysplasia with monoclonal rheumatoid factor and mixed cryoglobulinemia or hyperglobulinemic purpura, as well as monoclonal antibodies with ANA activity.<sup>88,89</sup>
3. Autoantibodies arising in patients with lymphoma as a result of immune dysregulation leading to vasculitis and SS like features;<sup>90</sup> this is particularly difficult to distinguish due to the increased frequency of lymphoma occurring in SS patients to know if the lymphoma arose in the setting of pre-existing SS.

## ISSUES OF VACCINATION

The relative risk of vaccination in the patient with autoimmune disease, particularly when receiving immunosuppressive therapy including corticosteroids or biologic agents, continues to be controversial.

In June 2008, the ACR Guidelines Taskforce Panel recommended that SS patients receiving leflunomide, methotrexate or sulfasalazine can be immunized with inactive viral vaccines (e.g., influenza and pneumococcal) in accordance with CDC recommendations. Among the vaccines for influenza, choices include either the "killed" vaccine or the "live" nasal attenuated vaccine that is routinely given to children.

ACR recommendations for the more common vaccinations are outlined below:

### A. For: Influenza

Immunosuppressed patients or pregnant women should be strongly encouraged to receive vaccination against influenza using the standard injectable inactivated flu vaccines. FluMist<sup>®</sup>, a live attenuated vaccine, should be avoided.

Because of the theoretical potential for transmission, it is preferred that health care workers and household contacts of immunosuppressed patients receive the standard injectable inactivated flu vaccines.

The other groups who should not receive the inactivated vaccine include:

1. Persons with a history of Guillain-Barré syndrome

2. Persons with a history of hypersensitivity, including anaphylaxis, to chicken eggs.

### B. For: Herpes Zoster

Live viral vaccine preparations (e.g., Zostavax) with "all biologic agents" should be avoided.

The ACR provides no directives on whether live zoster vaccines are safe with MTX, combination therapy with other DMARDs or corticosteroid use.

### C. Live Vaccines

In response to threats of bio-terrorism, recent suggestions from the US government have included giving live vaccines including smallpox, oral polio virus, measles-mumps-rubella, BCG, oral typhoid, varicella, yellow fever to selected populations of patients.

These questions are also relevant to patients traveling to countries where these infections are endemic. Initial potential concerns related to vaccination of patients with abnormal immunity included:

- a) failure to respond adequately to vaccination with resultant lack of protection from the target disease;
- b) a requirement for more frequent vaccination; or
- c) more severe or more frequent adverse effects related to the vaccination; particularly with live virus or bacterial vaccines.

Autoimmune patients including SS are partially protected by the influenza vaccine, but their level of protection is impaired by the underlying immune dysfunction as well as by medications. In particular, impairment of response to vaccine has persisted 6–10 months after treatment with rituximab. Previous influenza vaccination in rituximab-treated patients does increase pre- and post-vaccination titers, providing some defence to influenza strains. Disease activity was not influenced by the administration of the flu vaccine.

### D. Novel mucosal vaccines including those for Cholera

Although the developments in mucosal administered vaccines is attractive, their usefulness in humans has yet to be established.<sup>91</sup> It remains to be seen to what extent the safety and efficacy profiles established in animal models hold true in genetically diverse human subjects who also may differ significantly in their intestinal flora, nutritional status and previous immunological experience, all of which are factors that have

been found to affect mucosal vaccine efficacy. Indeed, several mucosal vaccines, including oral live cholera vaccine and rotavirus vaccine candidates, have been found to work less well in developing country settings than in industrialized countries.

The problem with pure recombinant or synthetic antigens used in modern day vaccines is that they are generally far less immunogenic than older style live or killed whole organism vaccines.<sup>92</sup>

With few exceptions, alum remains the sole adjuvant approved for human use in the majority of countries worldwide. Although alum is able to induce a good antibody (Th2) response, it has little capacity to stimulate the cellular (Th1) immune responses that are so important for protection against many pathogens. In addition, alum has the potential to cause severe local and systemic side effects including sterile abscesses, eosinophilia and myofascitis, although fortunately most of the more serious side effects are relatively rare. There is also community concern regarding the possible role of aluminum in stimulating autoimmune responses and neurodegenerative diseases.<sup>92</sup>

## SUMMARY

SS develops from the interaction of genetic and environmental factors. There are neural and hormonal connections that influence the onset and severity of the disease. It is likely that viral infection can create an inflammatory microenvironment that alters the disposition of apoptotic fragments that serve as autoantigens. Thus, the search for a single viral agent that is causative is likely to prove difficult. Attention has focused on viruses that have tropism for the salivary and lacrimal glands, particularly members of the herpesvirus family.

Other infectious agents may mimic the clinical appearance of SS. The occurrence of a positive ANA or RF may lead the physician to overlook other causes such as hepatitis viral infection, HIV, tuberculosis or other mycobacteria such as *M. leprae*, as well as syphilis (the great imitator). These infections may also co-exist in the patient who has SS, particularly in this environment of increasing world travel and patients treated with potent immune suppressant medications.

## REFERENCES

1. Bolstad AI, Haga HJ, Wassmuth R, Jonsson R. Monozygotic twins with primary Sjogren's syndrome. *J Rheumatol* 2000; 27: 2264-6.
2. Deafen D, Escalante A, Weinrib L, Horwitz D, Bachman B, Roy-Burman P, et al. A revised estimate of twin concordance in systemic lupus erythematosus. *Arthritis Rheum* 1992; 35: 311-8.
3. Hjelmervik TO, Petersen K, Jonassen I, Jonsson R, Bolstad AI. Gene expression profiling of minor salivary glands clearly distinguishes primary Sjögren's syndrome patients from healthy control subjects. *Arthritis Rheum* 2005; 52: 1534-44.
4. Tan E, Muro Y, Pollard K. Autoantibody-defined epitopes on nuclear antigens are conserved, conformation-dependent and active site regions. *Clin Exp Rheumatol* 1994; 12: S27-31.
5. Bolstad AI, Jonsson R. The role of apoptosis in Sjögren's syndrome. *Ann Med Interne (Paris)* 1998; 149: 25-9.
6. Maruyama T, Saito I, Hayashi Y, Kompfner E, Fox RI, Burton DR, et al. Molecular analysis of the human autoantibody response to alpha-fodrin in Sjögren's syndrome reveals novel apoptosis-induced specificity. *Am J Pathol* 2004; 165: 53-61.
7. Singh AK. Lupus in the Fas lane? *J R Coll Physicians Lond* 1995; 29: 475-8.
8. Fox RI. Sjögren's syndrome. *Lancet* 2005; 366: 321-31.
9. Arnett F. Histocompatibility typing in the rheumatic diseases: diagnostic and prognostic implications. *Med Clin NA* 1994; 20: 371-87.
10. Arnett FC, Hamilton RG, Reveille JD, Bias WB, Harley JB, Reichlin M. Genetic studies of Ro (SS-A) and La (SS-B) autoantibodies in families with systemic lupus erythematosus and primary Sjögren's syndrome. *Arthritis Rheum* 1989; 32: 413-9.
11. Harley J, Reichlin M, Arnett F, Alexander EL, Bias W, Provost T. Gene interaction at HLA-DQ enhances autoantibody production in primary Sjögren's syndrome. *Science* 1986; 232: 1145-7.
12. Adebajo A, Charles P, Maini R, Hazleman B. Autoantibodies in malaria, tuberculosis and hepatitis B in a West African population. *Clin Exp Immunol* 1993; 92: 73-6.
13. Petchclai B, Chuthanonndh R, Rungrueng S. Autoantibodies in leprosy among Thai patients. *Lancet* 1973; 301: 1481-2.
14. Kiyosawa K, Sodeyama T, Tanaka E, Gibo Y, Yoshizawa K, Nakano Y, et al. Interrelationship of blood transfusion, non-A, non-B hepatitis and hepatocellular carcinoma: analysis by detection of antibody to hepatitis C virus. *Hepatology* 1990; 12: 671-5.
15. Churchill M, Geraci J, Hunder G. Musculoskeletal manifestations of bacterial endocarditis. *Ann Intern Med* 1977; 87: 754.
16. Fox RI. Epidemiology, pathogenesis, animal models, and treatment of Sjögren's syndrome. *Curr Opin Rheumatol* 1994; 6: 501-8.
17. Fox RI, Chilton T, Scott S, Benton L, Howell FV, Vaughan JH. Potential role of Epstein-Barr virus in Sjögren's syndrome. *Rheum Dis Clin North Am* 1987; 13: 275-92.

18. Fox RI, Luppi M, Kang H-I, Pisa P. Reactivation of Epstein-Barr virus in Sjögren's syndrome. In: JW Sixbey TO, editor. Springer Seminar in Immunopathology. Heidelberg: Springer-Verlag, 1991: 217–31.
19. Jones DT, Monroy D, Ji Z, Atherton SS, Pflugfelder SC. Sjögren's syndrome: cytokine and Epstein-Barr viral gene expression within the conjunctival epithelium. *Invest Ophthalmol Vis Sci* 1994; 35: 3493–504.
20. Saito I, Servenius B, Compton T, Fox R. Detection of Epstein-Barr virus DNA by polymerase chain reaction in blood and tissue biopsies from patients with Sjögren's syndrome. *J Exp Med* 1989; 169: 2191–8.
21. Merne ME, Syrjanen SM. Detection of Epstein-Barr virus in salivary gland specimens from Sjögren's syndrome patients. *Laryngoscope* 1996; 106(12 Pt 1): 1534–9.
22. Karameris A, gorgoulis V, Iliopoulos A, Frangia C, et al. Detection of the Epstein-Barr viral genome by an in situ hybridization method in salivary gland biopsies from patients with secondary Sjögren's syndrome. *Clin Exp Rheumatol* 1992; 10: 327–32.
23. Kudo I, Saito I, Moro I. Detection of Epstein-Barr virus DNA from lacrimal gland biopsies in Sjögren's syndrome patients. *Clin Exp Rheum* 1991; 9: 337.
24. Pflugfelder SC, Crouse C, Pereira I, Atherton S. Amplification of Epstein-Barr virus genomic sequences in blood cells, lacrimal glands, and tears from primary Sjögren's syndrome patients. *Ophthalmology* 1990; 97: 976–84.
25. Mariette X. Sjögren's syndrome and virus. *Ann Med Interne (Paris)* 1995; 146: 243–6.
26. Mariette X, Cazals-Hatem D, Agbalika F, Selimi F, Brunet M, Morinet F, et al. Absence of cytomegalovirus and Epstein-Barr virus expression in labial salivary glands of patients with chronic graft-versus-host disease. *Bone Marrow Transplant* 1996; 17: 607–10.
27. Tateishi MS, Saito I, Yamamoto K, Miyasaka N. Spontaneous production of Epstein Barr virus by B lymphoblastoid cell lines obtained from patients with Sjögren's syndrome. *Arthritis Rheum* 1993; 36: 827–35.
28. Vaughan JH, Nguyen MD, Valbracht JR, Patrick K, Rhodes GH. Epstein-Barr virus-induced autoimmune responses. II. Immunoglobulin G autoantibodies to mimicking and non-mimicking epitopes. Presence in autoimmune disease. *J Clin Invest* 1995; 95: 1316–27.
29. Fox RI, Luppi M, Kang HI, Pisa P. Reactivation of Epstein-Barr virus in Sjögren's syndrome. *Springer Semin Immunopathol* 1991; 13: 217–31.
30. Inoue N, Miyasaka N, Harada S, Yanagi K. Analysis of antibody titers to Epstein-Barr virus nuclear antigens in sera of patients with Sjögren's syndrome and with rheumatoid arthritis. *J Infect Dis* 1991; 164: 22–8.
31. Marchini B, Dolcher MP, Sabbatini A, Klein G, Migliorini P. Immune response to different sequences of the EBNA I molecule in Epstein-Barr virus-related disorders and in autoimmune diseases. *J Autoimmun* 1994; 7: 179–91.
32. Miyasaka N, Saito I, Haruta J. Possible involvement of Epstein-Barr virus in the pathogenesis of Sjögren's syndrome. *Clin Immunol Immunopathol* 1994; 72: 166–70.
33. Yamazaki M, Kitamura R, Kusano S, Eda H, Sato S, Okawa-Takatsuji M, et al. Elevated immunoglobulin G antibodies to the proline-rich amino-terminal region of Epstein-Barr virus nuclear antigen-2 in sera from patients with systemic connective tissue diseases and from a subgroup of Sjögren's syndrome patients with pulmonary involvements. *Clin Exp Immunol* 2005; 139: 558–68.
34. Gaston JS, Rowe M, Bacon P. Sjögren's syndrome after infection by Epstein-Barr virus. *J Rheumatol* 1990; 17: 558–61.
35. Horiuchi M, Yamano S, Inoue H, Ishii J, Nagata Y, Adachi H, et al. Possible involvement of IL-12 expression by Epstein-Barr virus in Sjögren syndrome. *J Clin Pathol* 1999; 52: 833–7.
36. Fox RI, Luppi M, Pisa P, Kang HI. Potential role of Epstein-Barr virus in Sjögren's syndrome and rheumatoid arthritis. *J Rheumatol Suppl* 1992; 32: 18–24.
37. Eguchi K, Matsuoka N, Ida H, Nakashima M, et al. Primary Sjögren's syndrome with antibodies to HTLV-1: clinical and laboratory features. *Ann Rheum Dis* 1992; 51: 769–76.
38. Green JE, Hinrichs SH, Vogel J, Jay G. Exocrinopathy resembling Sjögren's syndrome in HTLV-1 tax transgenic mice. *Nature* 1989; 341: 72–4.
39. Terada K, Katamine S, Eguchi K, Moriuchi R, Kita M, Shimada H, et al. Prevalence of serum and salivary antibodies to HTLV-1 in Sjögren's syndrome. *Lancet* 1994; 344: 1116–9.
40. Garry RF. New evidence for involvement of retroviruses in Sjögren's syndrome and other autoimmune diseases. *Arthritis Rheum* 1994; 37: 465–9.
41. Garry R, Fermin C, Hart D, Alexander S, Donehower L, Luo-Zhang H. Detection of a human intracisternal A-type retroviral particle antigenically related to HIV. *Science* 1990; 250: 1127.
42. Fierabracci A, Upton CP, Hajibagheri N, Bottazzo GF. Lack of detection of retroviral particles (HIAP-1) in the H9 T cell line co-cultured with thyrocytes of Graves' disease. *J Autoimmun* 2001; 16: 457–62.
43. Kalden JR, Gay S. Retroviruses and autoimmune rheumatic diseases. *Clin Exp Immunol* 1994; 98: 1–5.
44. Zucker-Franklin D. Non-HIV retroviral associations with rheumatic disease. *Curr Rheumatol Rep* 2000; 2: 156–62.
45. Perl A. Endogenous retroviruses in pathogenesis of autoimmunity. *J Rheumatol* 2001; 28: 461.
46. Kim H, Takenaka O, Crow T. Cloning and nucleotide sequence of retroposons specific to hominoid primates derived from an

- endogenous retrovirus (HERV-K). *AIDS research and human retroviruses*. 1999; 15: 595–601.
47. Kjellman C, Sjögren HO, Salford LG, Widegren B. HERV-F (XA34) is a full-length human endogenous retrovirus expressed in placental and fetal tissues. *Gene* 1999; 239: 99–107.
  48. Hishikawa T, Ogasawara H, Kaneko H, Shirasawa T, Matsuura Y, Sekigawa I, et al. Detection of antibodies to a recombinant gag protein derived from human endogenous retrovirus clone 4-1 in autoimmune diseases. *Viral Immunol* 1997; 10: 137–47.
  49. Li JM, Fan WS, Horsfall AC, Anderson AC, Rigby S, Larsson E, et al. The expression of human endogenous retrovirus-3 in fetal cardiac tissue and antibodies in congenital heart block. *Clin Exp Immunol* 1996; 104: 388–93.
  50. Andersson G, Svensson A, Setterblad N, Rask L. Retroelements in the human MHC class II region. *Trends Genet* 1998; 14: 109–14.
  51. Rigby S, Cooke S, Weerasingh D, Venables P. Absence of HTLV-1 tax in Sjögren's syndrome. *Arthritis Rheum* 1996; 39: 1609–10.
  52. Shattles WG, Brookes SM, Venables PJ, Clark DA, Maini RN. Expression of antigen reactive with a monoclonal antibody to HTLV-1 P19 in salivary glands in Sjögren's syndrome. *Clin Exp Immunol* 1992; 89: 46–51.
  53. Stathopoulou E, Routsias J, Stea E, Moutsopoulos H, Tzioufas A. Cross-reaction between antibodies to the major epitope of Ro60 kD autoantigen and a homologous peptide of Coxsackie virus 2B protein. *Clin Exp Immunol* 2005; 141: 148–54.
  54. Stathopoulou EA, Routsias JG, Stea EA, Moutsopoulos HM, Tzioufas AG. Cross-reaction between antibodies to the major epitope of Ro60 kD autoantigen and a homologous peptide of Coxsackie virus 2B protein. *Clin Exp Immunol* 2005; 141: 148–54.
  55. Gottenberg JE, Pallier C, Ittah M, Lavie F, Miceli-Richard C, Sellam J, et al. Failure to confirm coxsackievirus infection in primary Sjögren's syndrome. *Arthritis Rheum* 2006; 54: 2026–8.
  56. Coll J, Gambus G, Corominas J, Tomas S, Esteban JI, Guardia J. Immunohistochemistry of minor salivary gland biopsy specimens from patients with Sjögren's syndrome with and without hepatitis C virus infection. *Ann Rheum Dis* 1997; 56: 390–2.
  57. Haddad J, Deny P, Munz-Gotheil C, Ambrosini JC. Lymphocytic sialadenitis of Sjögren's syndrome associated with chronic hepatitis C virus liver disease. *Lancet* 1992; 8: 321–3.
  58. Koike K, Moriya K, Ishibashi K, Yotsuyanagi H, Shintani Y, Fujie H, et al. Sialadenitis histologically resembling Sjögren syndrome in mice transgenic for hepatitis C virus envelope genes. *Proc Nat Acad Sci* 1997; 94: 233–6.
  59. Arrieta JJ, Rodriguez-Inigo E, Ortiz-Movilla N, Bartolome J, Pardo M, Manzarbeitia F, et al. In situ detection of hepatitis C virus RNA in salivary glands. *Am J Pathol* 2001; 158: 259–64.
  60. De Re V, De Vita S, Gasparotto D, Marzotto A, Carbone A, Ferraccioli G, et al. Salivary gland B cell lymphoproliferative disorders in Sjögren's syndrome present a restricted use of antigen receptor gene segments similar to those used by hepatitis C virus-associated non-Hodgkins's lymphomas. *Eur J Immunol* 2002; 32: 903–10.
  61. Ramos-Casals M, Garcia-Carrasco M, Cervera R, Font J. Sjögren's syndrome and hepatitis C virus. *Clin Rheumatol* 1999; 18: 93–100.
  62. Fox RI. Sjögren's syndrome. Controversies and progress. *Clin Lab Med* 1997; 17: 431–44.
  63. Fox RI. Sjögren's syndrome. *Curr Opin Rheumatol* 1995; 7: 409–16.
  64. Akriviadis EA, Xanthakis I, Navrozidou C, Papadopoulos A. Prevalence of cryoglobulinemia in chronic hepatitis C virus infection and response to treatment with interferon-alpha. *J Clin Gastroenterol* 1997; 25: 612–8.
  65. Buezo GF, Garcia-Buey M, Rios-Buceta L, Borque MJ, Aragues M, Dauden E. Cryoglobulinemia and cutaneous leukocytoclastic vasculitis with hepatitis C virus infection. *Int J Dermatol* 1996; 35: 112–5.
  66. Cardinali C, Gerlini G, Caproni M, Pimpinelli N, Fabbri P. Hepatitis C virus: a common triggering factor for both nodular vasculitis and Sjögren's syndrome? [letter]. *Br J Dermatol* 2000; 142: 187–9.
  67. Unoki H, Moriyama A, Tabaru A, Masumoto A, Otsuki M. Development of Sjögren's syndrome during treatment with recombinant human interferon-alpha-2b for chronic hepatitis C. *J Gastroenterol* 1996; 31: 723–7.
  68. Ferri C, La Civita L, Longombardo G, Zignego AL, Pasero G. Mixed cryoglobulinaemia: a cross-road between autoimmune and lymphoproliferative disorders. *Lupus* 1998; 7: 275–9.
  69. Mariette X. The hepatitis C virus and systemic diseases. *Rev Rhum Engl Ed* 1998; 65: 737–40.
  70. Klemola E, Kaariainen L. Cytomegalovirus as a possible cause of a disease resembling infectious mononucleosis. *Br Med J* 1965; 2: 1099.
  71. Maitland N, Flint S, Scully C, Crean SJ. Detection of cytomegalovirus and Epstein-Barr virus in labial salivary glands in Sjögren's syndrome and non-specific sialadenitis. *J Oral Pathol Med* 1995; 24: 293–8.
  72. Venables P, Ross M, Charles P, Melsom R, Griffiths P, Maini R. A seroepidemiological study of cytomegalovirus and Epstein-Barr virus in rheumatoid arthritis and sicca syndrome. *Ann Rheum Dis* 1985; 44: 742.
  73. Newkirk M, Duffy K, Leclerc J, Lambert N, Shiroky J. Detection of cytomegalovirus, Epstein-Barr virus and herpes virus-6

- in patients with rheumatoid arthritis with or without Sjögren's syndrome. *Rheumatology* 1994; 33: 317.
74. Fox RI, Saito I, Chan EK, Josephs S, Salahuddin SZ, Ahlashi DV, et al. Viral genomes in lymphomas of patients with Sjögren's syndrome. *J Autoimmun* 1989; 2: 449–55.
  75. Itescu S, Brancato L, Buxbaum J, Gregersen P, Rizk C, Croxson T, et al. A diffuse infiltrative CD8 lymphocytosis syndrome in human immunodeficiency virus (HIV) infection: a host immune response associated with HLA-DR5. *Ann Intern Med* 1990; 112: 3.
  76. Savige J, Chang L, Horn S, Crowe S. Anti-nuclear, anti-neutrophil cytoplasmic and anti-glomerular basement membrane antibodies in HIV-infected individuals. *Autoimmunity* 1994; 18: 205–11.
  77. Anderson L, Cummings N, Asofsky R, Hylton M, Tarpley T Jr, Tomasi T Jr, et al. Salivary gland immunoglobulin and rheumatoid factor synthesis in Sjögren's syndrome: natural history and response to treatment. *Am J Med* 1972; 53: 456–63.
  78. Şoglu Y, Erdamar B, Ihan, Katircioglu O, evikbas U. Tuberculosis of the parotid gland. *J Laryngol Otol* 2007; 112: 588–91.
  79. Kim Y, Jeong W, Jung K, Sung M, Kim K, Kim C. Diagnosis of major salivary gland tuberculosis: experience of eight cases and review of the literature. *Acta otolaryngologica* 2005; 125: 1318–22.
  80. Isenberg D, Maddison P, Swana G, Skinner R, Swana M, Jones M, et al. Profile of autoantibodies in the serum of patients with tuberculosis, klebsiella and other gram-negative infections. *Clin Exp Immunol* 1987; 67: 516.
  81. Lindqvist K, Coleman R, Osterland C. Autoantibodies in chronic pulmonary tuberculosis. *J Chronic Dis* 1970; 22: 717–25.
  82. Shoenfeld Y, Vilner Y, Coates A, Rauch J, Lavie G, Shaul D, et al. Monoclonal anti-tuberculosis antibodies react with DNA, and monoclonal anti-DNA autoantibodies react with *Mycobacterium tuberculosis*. *Clin Exp Immuno* 1986; 66: 255.
  83. Southam J, Venkataraman B. Oral manifestations of leprosy. *Br J Oral Surg* 1973; 10: 272–9.
  84. Sekhar G, Vance G, Otton S, Kumar S, Stanley J, Rao G. Ocular manifestations of Hansen's disease. *Doc Ophthalmol* 1994; 87: 211–21.
  85. Dana M, Hochman M, Viana M, Hill C, Sugar J. Ocular manifestations of leprosy in a noninstitutionalized community in the United States. *Arch Ophthalmol* 1994; 112: 626.
  86. Reichart P, Samaranayake L, Samaranayake Y, Grote M, Pow E, Cheung B. High oral prevalence of *Candida krusei* in leprosy patients in Northern Thailand. *J Clin Microbiol* 2002; 40: 4479.
  87. Manley G, Wong E, Dalmau J, Elkouf K, Posner J, Furneaux H. Sera from some patients with antibody-associated paraneoplastic encephalomyelitis/sensory neuronopathy recognize the Ro-52K antigen. *J Neurooncol* 1994; 19: 105–12.
  88. Capra J, Winchester R, Kunkel H. Hypergammaglobulinemic purpura: studies on the unusual anti-[gamma]-globulins characteristic of the sera of these patients. *Medicine* 1971; 50: 125.
  89. Ferri C, Sebastiani M, Giuggioli D, Cazzato M, Longombardo G, Antonelli A, et al. Mixed cryoglobulinemia: demographic, clinical, and serologic features and survival in 231 patients. In: Elsevier, 2004: 355–74.
  90. Miller D. The association of immune disease and malignant lymphoma. *Ann Intern Med* 1967; 66: 507.
  91. Holmgren J, Czerkinsky C. Mucosal immunity and vaccines. *Nat Med* 2005; 11: S45–53.
  92. Petrovsky N, Aguilar J. Vaccine adjuvants: current state and future trends. *Immunol Cell Biol* 2004; 82: 488–96.
  93. Colmegna I, Koehler J, Garry R, Espinoza L. Musculoskeletal and autoimmune manifestations of HIV, syphilis and tuberculosis. *Curr Opin Rheumatol* 2006; 18: 88.
  94. Arrieta J, Rodriguez-Inigo E, Ortiz-Movilla N, Bartolomé J, Pardo M, Manzarbeitia F, et al. In situ detection of hepatitis C virus RNA in salivary glands. *Am J Pathol* 2001; 158: 259.
  95. Pawlotsky J, Yahia M, Andre C, Voisin M, Intrator L, Roudot-Thoraval F, et al. Immunological disorders in C virus chronic active hepatitis: a prospective case-control study. *Hepatology* 1994; 19: 841–8.
  96. Trapani S, Einmini M, Falcini F. Human parvovirus B19 infection: its relationship with systemic lupus erythematosus. In: Elsevier, 1999: 319–25.
  97. Adebajo A. Dengue arthritis. *Rheumatology* 1996; 35: 909.
  98. Yung R, Richardson B. Drug-induced lupus. *Rheum Dis Clin North Am* 1994; 20: 61.